


RESEARCH ARTICLE

Open Access



Feasibility and effectiveness of a single-catheter approach for adrenal vein sampling in patients with primary aldosteronism

Jindong Wan^{1,2}, Fei Ran^{1,2}, Siwei Xia^{1,2}, Jixin Hou^{1,2}, Dan Wang^{1,2}, Sen Liu^{1,2}, Yi Yang^{1,2}, Peng Zhou^{1,2} and Peijian Wang^{1,2*} 

Abstract

Background: Adrenal vein sampling (AVS) is the preferred method for subtyping patients with primary aldosteronism, while the procedure is technically challenging. This study evaluated the feasibility and effectiveness of a single-catheter approach for AVS.

Methods: A retrospective analysis of 106 consecutive patients who underwent AVS was performed to determine the procedural success and complication rates. Bilateral AVS procedures were performed using a single 5-Fr Tiger catheter with repeated manual reshaping.

Results: We successfully advanced the catheter into the bilateral adrenal veins of all patients and reached a 90.6% procedural success rate of AVS. The procedural period was 33.0 ± 8.2 min, the fluoroscopy period was 5.8 ± 1.7 min, and the diagnostic contrast used was 17.3 ± 5.5 ml. Only one patient (0.9%) had a hematoma at the femoral puncture site. No other complications were observed. The operation period gradually shortened as the cumulative number of operations increased. The number of procedures required to overcome the learning curve was about 33 cases.

Conclusions: The single-catheter approach is feasible and effective for AVS. Moreover, this approach required a relatively short learning curve for an inexperienced trainee.

Keywords: Adrenal vein sampling, Primary aldosteronism, Single catheter, Adrenal adenomas, Hypertension

Background

Approximately 44.7% of Chinese adults aged 35–75 years have hypertension, and it was estimated that 244.5 million Chinese adults experienced hypertension [1, 2]. Primary aldosteronism (PA) is the most common cause of secondary hypertension with a prevalence of at least 4% in patients with newly diagnosed hypertension in

Chinese population [3]. PA is associated with increased risk of cardiovascular disease compared with patients with primary hypertension [4]. Fortunately, nearly half of patients with PA that is due to an unilateral aldosterone-producing adenoma can be cured by adrenalectomy [5]. Aldosterone-producing adenoma and bilateral idiopathic adrenocortical hyperplasia are the two most common types of PA, while patients with the latter are unsuitable for adrenalectomy but need lifelong treatment with mineralocorticoid receptor antagonists. Therefore, appropriately selecting patients for unilateral adrenalectomy is critical in the differential diagnosis and subtyping of

* Correspondence: 23772194@qq.com

¹Department of Cardiology, The First Affiliated Hospital, Chengdu Medical College, Chengdu 610500, Sichuan, China

²Key Laboratory of Aging and Vascular Homeostasis of Sichuan Higher Education Institutes, The First Affiliated Hospital, Chengdu Medical College, Chengdu 610500, Sichuan, China



© The Author(s). 2021 **Open Access** This article is licensed under a Creative Commons Attribution 4.0 International License, which permits use, sharing, adaptation, distribution and reproduction in any medium or format, as long as you give appropriate credit to the original author(s) and the source, provide a link to the Creative Commons licence, and indicate if changes were made. The images or other third party material in this article are included in the article's Creative Commons licence, unless indicated otherwise in a credit line to the material. If material is not included in the article's Creative Commons licence and your intended use is not permitted by statutory regulation or exceeds the permitted use, you will need to obtain permission directly from the copyright holder. To view a copy of this licence, visit <http://creativecommons.org/licenses/by/4.0/>. The Creative Commons Public Domain Dedication waiver (<http://creativecommons.org/publicdomain/zero/1.0/>) applies to the data made available in this article, unless otherwise stated in a credit line to the data.

patients with PA. The current clinical practice guidelines recommend adrenal vein sampling (AVS) as a preferred method to differentiate unilateral from bilateral PA and to select patients with PA for unilateral adrenalectomy [6–8].

Although AVS is accepted as the gold standard test for subtyping PA, the procedure is underused especially in underdeveloped areas partially because the AVS procedure is technically challenging and relatively expensive [9]. Due to the anatomical complexity and variations, AVS fails frequently even in experienced hands [10]. In addition, the AVS procedure can have various complications including hematoma at the puncture site, venous dissection and thrombosis, and adrenal hemorrhage and insufficiency. Previous studies reported variable success rates of the AVS procedure ranging from 40 to 94% [10–12]. Catheterization into the right adrenal vein is particularly difficult as it is a small and short vessel which directly drains into the inferior vena cava (IVC). Because of the distinct anatomy of the left and right adrenal veins, two different catheters are usually used in the AVS procedure, which may increase the cost of this invasive test.

As mentioned, AVS is an optimal test for differential diagnosis and subtyping of patients with PA, but it is an invasive, relatively expensive procedure with technical challenges and varied success rates. The present study aimed to evaluate the feasibility and effectiveness of a single-catheter approach for AVS in patients with PA.

Methods

Patients

This retrospective study was approved by the Institutional Review Board of the First Affiliated Hospital of Chengdu Medical College. All patients had given their written consent for the AVS procedure and participation in the study. We enrolled 106 consecutive patients who were diagnosed PA and underwent the AVS procedure from October 2018 to April 2020. We only used the single-catheter technique for AVS during this period of time in our center. The inclusion criteria included diagnosis of PA by clinical and laboratory examinations including saline-loading test and completion of adrenal computed tomography scan. Patients with severe hepatic and renal disorders were excluded.

AVS procedure

Patients were prepared for the AVS procedure according to the guidelines [13]. Briefly, antihypertensive medications were switched to peripheral α 1-adrenergic receptor blockers and/or long-acting calcium-channel blockers 4 weeks before the AVS procedure. Hypokalemia, if present, were corrected with potassium supplements before the procedure. The patients were kept in the supine

position for 1 h before AVS. AVS was performed in the morning by two inexperienced fellows who were recently enrolled in the interventional cardiology fellowship program. A 5-Fr sheath was percutaneously placed into the right common femoral vein under local anesthesia. A 5-Fr Tiger catheter (Terumo, Tokyo, Japan) was manually reshaped for the right adrenal vein catheterization by slightly stretching the secondary and tertiary curves from 135° to 150° (Fig. 1a and b). The reshaped catheter was inserted into the IVC and then into the superior vena cava using a guidewire (0.035-in. loach guidewire, Terumo Corporation, Tokyo, Japan), and a 5 ml sample of blood was drawn from each site (Fig. 2a and b). The right adrenal vein was catheterized by attempting canalization at around the level of the eleventh thoracic vertebra (Fig. 2c). Catheterization into the right adrenal vein was confirmed by angiography (Fig. 2c). After drawing a 5 ml sample of blood from the right adrenal vein, the catheter was withdrawn and manually reshaped again for the left adrenal vein catheterization by further stretching the secondary and tertiary curves from 150° to 165° (Fig. 1c). The reshaped catheter was inserted again into the IVC, and catheterization into the left adrenal vein was confirmed by angiography (Fig. 2d). After drawing a 5 ml sample of blood from the right adrenal vein, the catheter was withdrawn. At the end of the procedure, the sheath was removed, and a 10 min manual compression was applied for hemostasis.

Data collection

The demographic and laboratory data and procedural factors including period of procedure, fluoroscopy time, and procedural success and complication rates were collected from record reviewing (Table 1). The success of AVS was defined as the adrenal/peripheral vein cortisol ratio is more than 2:1 without cosyntropin.

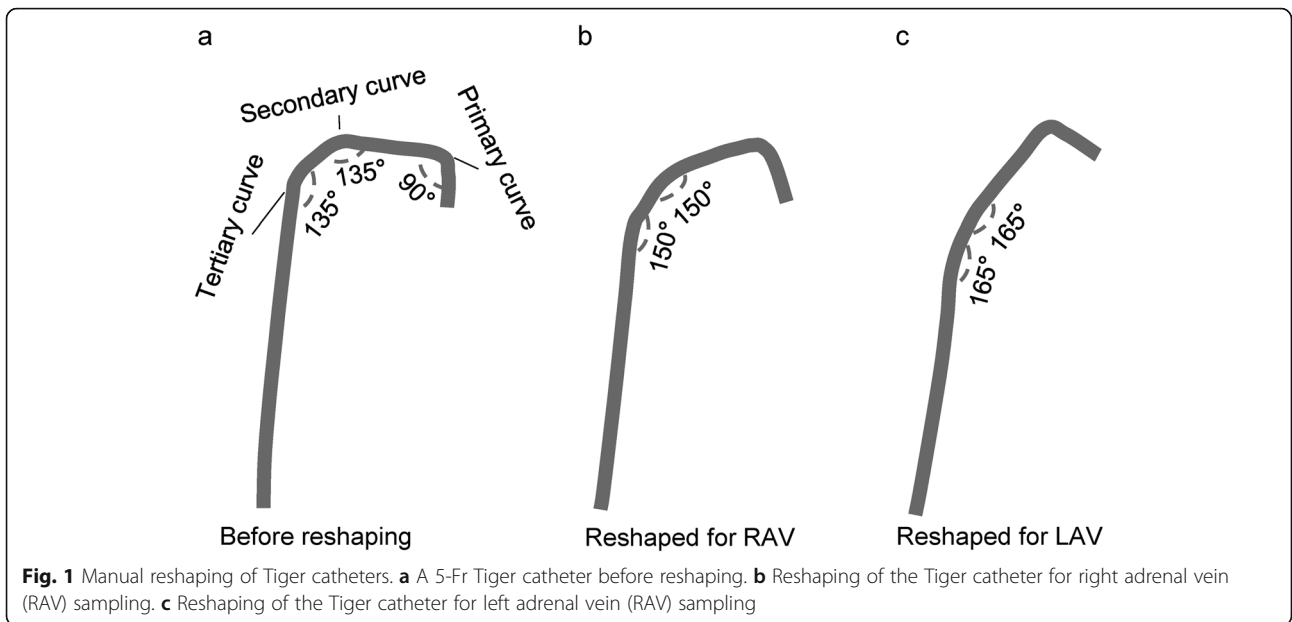
Statistical analysis

Continuous data are presented as mean \pm standard deviation, while categorical data are presented by frequency with percentage or range. A learning curve was drawn based on a cumulative sum (CUSUM) analysis for procedure time. The operation time for each case is defined as x_i , and the mean procedure time of all the cases is defined as μ . Therefore, the CUSUM at procedure time is calculated as $\sum_{i=1}^n (x_i - \mu)$ [14]. The CUSUM was plotted against the case number.

Results

Success rate of AVS procedure

The single Tiger catheter was successfully inserted into the right and left adrenal veins in all 106 patients. The



success rate of bilateral AVS was 90.6% (96 out of 106) (Table 1). The procedural and fluoroscopy time was 33.0 ± 8.2 min and 5.8 ± 1.7 min, respectively (Table 1). The radiation exposure for each procedure was 117.3 ± 25.5 mGy, and the contrast agent used per procedure was 17.3 ± 5.5 ml (Table 1). Only 1 patient (0.9%) had a

Table 1 Patient demographics, laboratory, and procedural data

Items	Data
Age, year	55.4 ± 12.3
Male, n (%)	59 (55.7)
History of hypertension, year	8.5 ± 4.2
Systolic blood pressure, mmHg	147 ± 24
Diastolic blood pressure, mmHg	94 ± 14
Creatinine, μmol/l	68.5 ± 22.3
Plasma potassium, mmol/l	3.4 ± 0.2
Urine potassium, mmol/l	42.5 ± 20.5
Aldosterone renin ratio, pg/ml to ng/(ml·h)	455.9 ± 32.7
Plasma aldosterone before salt loading, ng/l	345.7 ± 132.4
Plasma aldosterone after salt loading, ng/l	192.8 ± 106.5
Success rates of AVS, case (%)	
Left AVS	99 (93.4%)
Right AVS	97 (91.5%)
Bilateral AVS	96 (90.6%)
Procedural time, min	33.0 ± 8.2
Fluoroscopy time, min	5.8 ± 1.7
Radiation dosage, mGy	117.3 ± 25.5
diagnostic contrast, ml	17.3 ± 5.5
Complications, n (%)	
Hematoma at the femoral puncture site	1 (0.9)

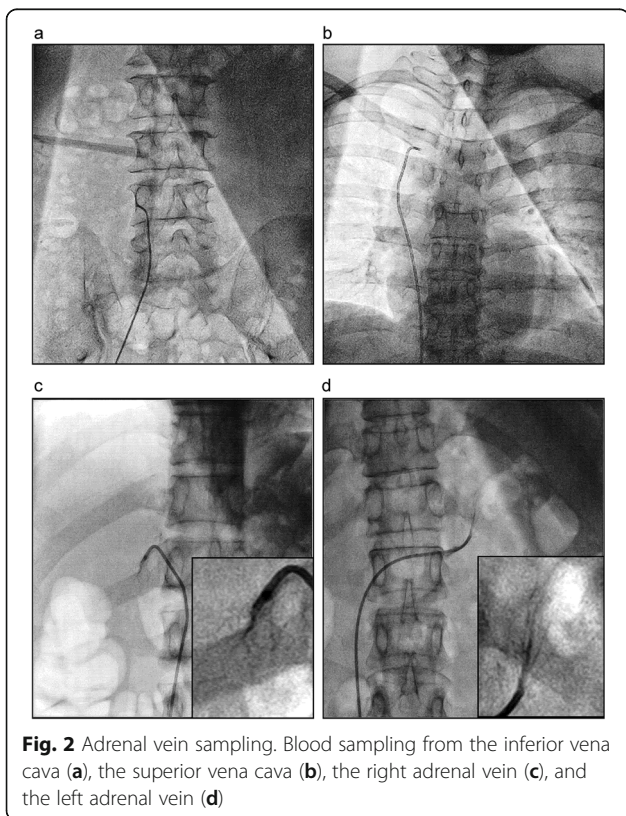


Fig. 2 Adrenal vein sampling. Blood sampling from the inferior vena cava (a), the superior vena cava (b), the right adrenal vein (c), and the left adrenal vein (d)

AVS Adrenal vein sampling

hematoma at the femoral puncture site. No other procedure-related complications were observed.

Canalization of the right adrenal vein

Canalization of the right adrenal vein is critical for success of AVS but particularly challenging. The location of the right adrenal vein orifice at the IVC varies from the lower part of the tenth thoracic vertebra and the upper part of the first lumbar vertebra (Fig. 3). Most (79.2%) right adrenal veins drain into the IVC between the middle part of the eleventh thoracic vertebra and the middle part of the twelfth thoracic vertebra (Fig. 3). The angle between the right adrenal vein and the IVC is 57.3 ± 32.5 degree (ranging between 5 to 115 degree) (Fig. 4).

Learning curve of AVS

The CUMSUM of procedure duration was plotted against case number. Among the 106 consecutive patients, the CUMSUM value inflected at patient number 33 (Fig. 5). Patients 1–32 constituted the learning phase of the curve with procedure duration of 49 ± 14 min, while patients 34–106 consisted of the experienced phase with procedure duration of 30 ± 5 min (Fig. 5).

Discussion

This study demonstrates that the single-catheter approach is a feasible, effective, and easy-to-learn method for AVS in patients with PA. We found that the single-catheter approach achieved a procedural success rate of 90.6% for bilateral AVS with very minor complications.

AVS has long been considered as a challenging procedure even in experienced hands, and it needs a relatively long learning period [11, 15]. The procedural success rate varies in a broad range and can be as low as around 30% [16, 17]. Although the success rate in the present study is high, we could not make conclusion that the single-catheter approach has higher success rate than other techniques without head-to-head comparisons. The difficulties of the AVS procedure come from the anatomic complexities and variations of the adrenal veins, especially the right adrenal vein. Since the right and left adrenal veins drain into the IVC through distinct courses with different angles, two different catheters are usually used. The Tiger catheter has been used to canalize the left adrenal vein by other groups [18]. The present study demonstrated that a simple manual reshaping could make the Tiger catheter for both left and right adrenal vein catheterization. A couple of alternative methods have been developed to improve the right adrenal vein canalization. Specially designed catheters are available for the right adrenal vein sampling [19]. In addition, microcatheters have been used to facilitate the right adrenal vein canalization and to avoid mistakenly sampling from the common trunk of the accessory hepatic and the right adrenal vein [19, 20]. The approaches of using a special catheter or a microcatheter could improve procedural success rate, however, they may increase cost. Technical challenging and expensive materials may impede the wide application of AVS for the subtyping of patients with

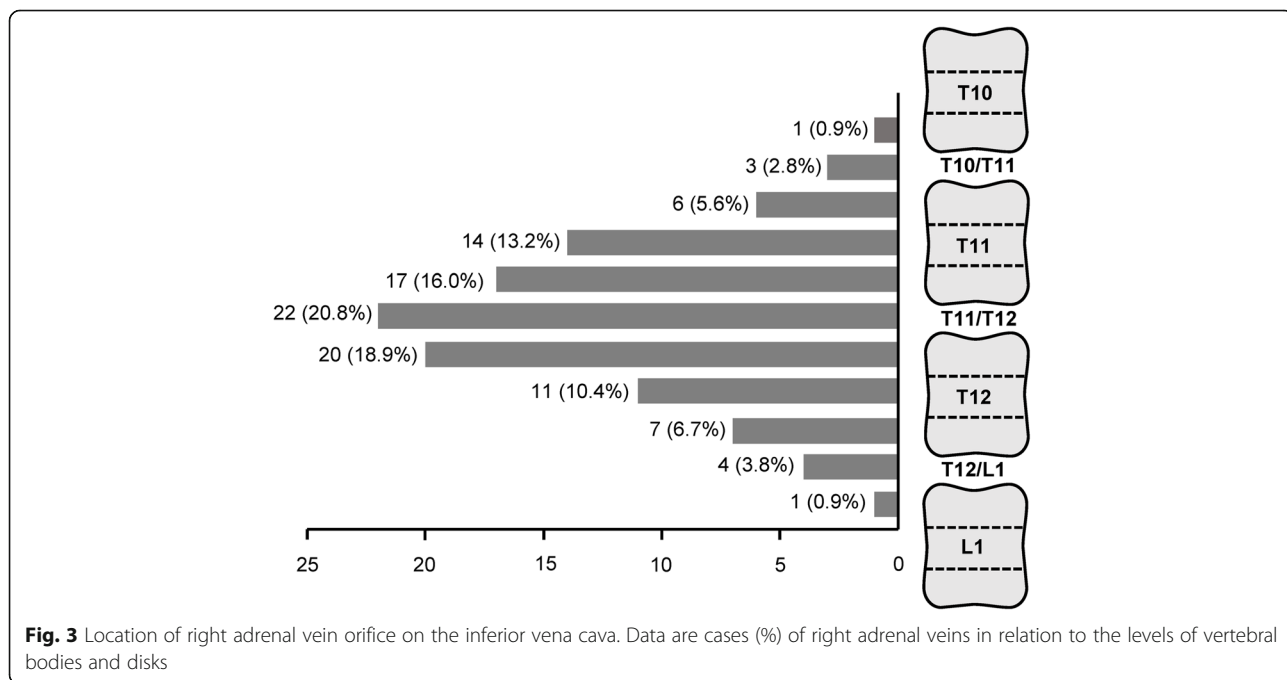
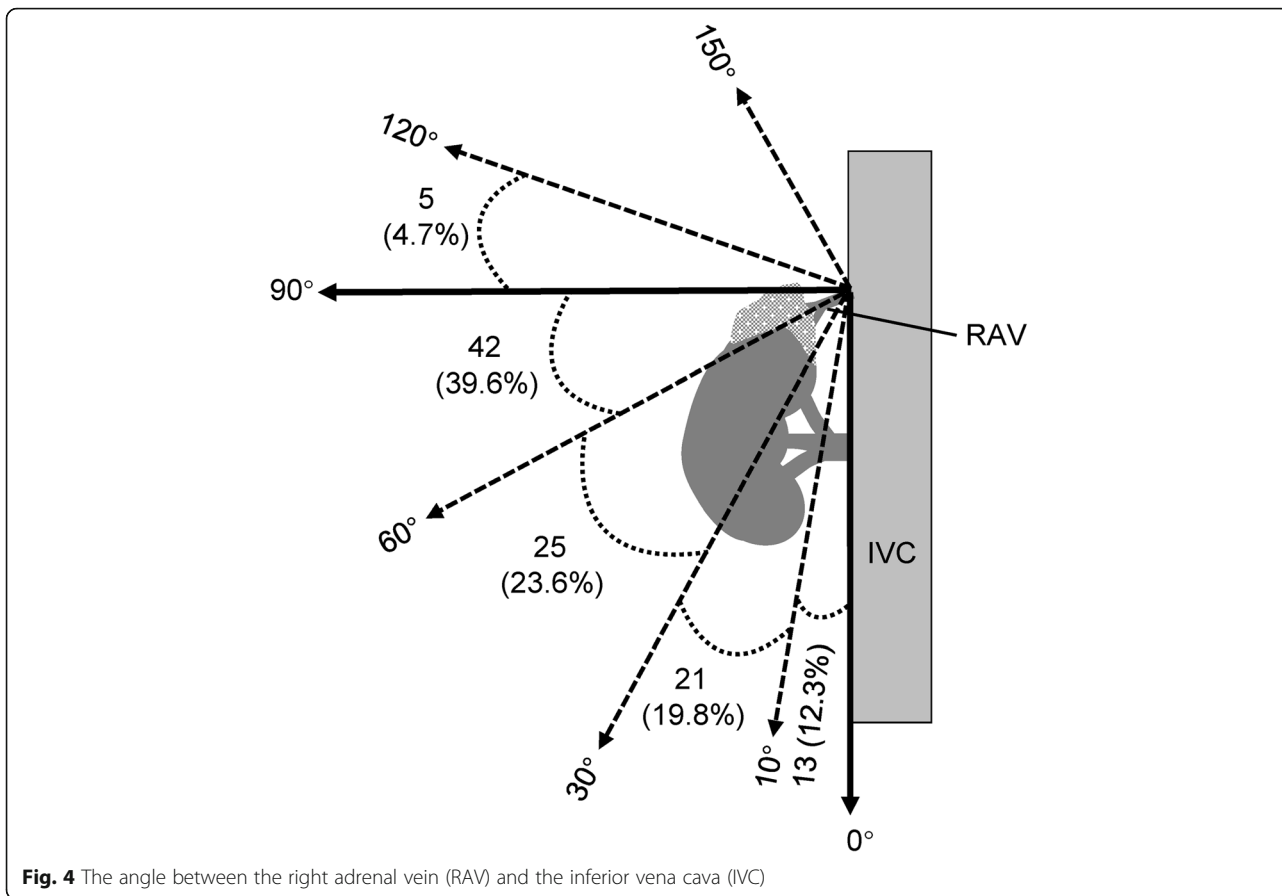


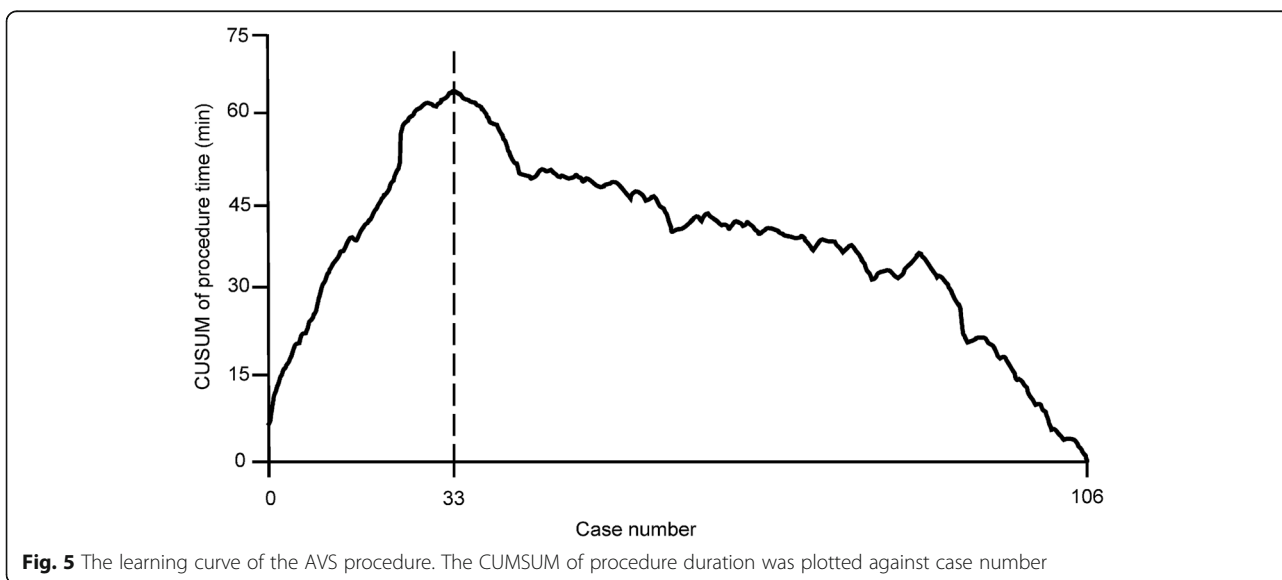
Fig. 3 Location of right adrenal vein orifice on the inferior vena cava. Data are cases (%) of right adrenal veins in relation to the levels of vertebral bodies and disks



PA. The single-catheter approach with manual re-shaping provides an alternative method to complete AVS.

Catheterization of the right adrenal vein is particularly challenging because it is a relatively small sized vein with anatomical variations. Therefore, localizing the right

adrenal vein during AVS is critical for technical success. Matsuura et al. investigated the anatomy of the right adrenal vein using multidetector computed tomography and demonstrated that the orifice of the right adrenal vein was located between the level of the eleventh thoracic and the first lumbar vertebrae, with the majority at



a level ranging from the middle third of the twelfth thoracic vertebra to the superior third of the first lumbar vertebra [21]. In the 106 patients enrolled in the preset study, the orifice of most right adrenal veins is slightly higher, i.e. between the middle part of the eleventh thoracic vertebra and the middle part of the twelfth thoracic vertebra. A previous study showed that the anatomical variations of the right adrenal vein based on computed tomography are highly concordant with the findings of angiography [22]. Therefore, computed tomography may provide useful information for localizing the right adrenal vein before AVS. In consistent with the previous study [21], the angle at which the right adrenal vein drains into the IVC varies between 5 to 115 degree in the present observation. As the majority of the right adrenal veins flow into the IVC with an acute angle, some groups suggested performing AVS via the forearm veins as an alternative route to the femoral vein [18].

One of the limitations is that this is a single-arm study. We could not make conclusion regarding whether the single-catheter technique is superior to or easier and cheaper than other AVS approaches. Further head-to-head comparisons are needed to answer those questions in the future. Another limitation is that pharmacological stimulation was not used during sequential AVS. Stress-induced fluctuations in cortisol and aldosterone secretion might affect the lateralization ratio. Although AVS was performed in the morning after the patients kept in the supine position for 1 h to minimize stress, it is better to apply cosyntropin stimulation before sequential AVS.

Conclusions

In conclusion, the single-catheter approach with repeated manual reshaping provides a feasible and effective method for the AVS procedure.

Abbreviations

AVS: Adrenal vein sampling; PA: Primary aldosteronism;; IVC: Inferior vena cava; CUSUM: Cumulative sum

Acknowledgements

None.

Authors' contributions

PW designed the study and completed the writing of the paper. JW, FR, SX, JH, DW, SL, YY, and PZ collected the data and performed data analysis. All authors confirmed the final version of the paper. The author(s) read and approved the final manuscript.

Funding

This research was supported by grants from the National Natural Science Foundation of China (81970262), the Central Funds Guiding the Local Science and Technology Development of Sichuan Province (2020ZYD036), the Innovation Team Project Department of Education of Sichuan Province (NO.17TD0011, 18TD0030), and Specialized Scientific Research Funding for Sichuan Center of Geriatrics (SCLNZX1808). The funding bodies played no role in the design of the study and collection, analysis, and interpretation of data and in writing the manuscript.

Availability of data and materials

Data relevant to this study are available from the corresponding authors upon reasonable request.

Ethics approval and consent to participate

This retrospective study was approved by the Institutional Review Board of the First Affiliated Hospital of Chengdu Medical College. All patients had given their written consent for the AVS procedure and participation in the study. The Institutional Review Board of the First Affiliated Hospital of Chengdu Medical College granted permission to access the raw data for the study.

Consent for publication

Not applicable.

Competing interests

All authors have no conflict of interest.

Received: 22 September 2020 Accepted: 24 January 2021

Published online: 30 January 2021

References

- Lu J, Lu Y, Wang X, Li X, Linderman GC, Wu C, Cheng X, Mu L, Zhang H, Liu J, et al. Prevalence, awareness, treatment, and control of hypertension in China: data from 1.7 million adults in a population-based screening study (China PEACE million persons project). *Lancet*. 2017;390(10112):2549–58.
- Wang Z, Chen Z, Zhang L, Wang X, Hao G, Zhang Z, Shao L, Tian Y, Dong Y, Zheng C, et al. Status of hypertension in China: results from the China hypertension survey, 2012–2015. *Circulation*. 2018;137(22):2344–56.
- Xu Z, Yang J, Hu J, Song Y, He W, Luo T, Cheng Q, Ma L, Luo R, Fuller PJ, et al. Primary Aldosteronism in patients in China with recently detected hypertension. *J Am Coll Cardiol*. 2020;75(16):1913–22.
- Mulatero P, Monticone S, Bertello C, Viola A, Tizzani D, Iannaccone A, Crudo V, Burrello J, Milan A, Rabbia F, et al. Long-term cardio- and cerebrovascular events in patients with primary aldosteronism. *J Clin Endocrinol Metab*. 2013;98(12):4826–33.
- Deinum J, Prejbisz A, Lenders JWM, van der Wilt GJ. Adrenal vein sampling is the preferred method to select patients with primary Aldosteronism for adrenalectomy: con side of the argument. *Hypertension*. 2018;71(1):10–4.
- Funder JW, Carey RM, Mantero F, Murad MH, Reincke M, Shibata H, Stowasser M, Young WF Jr. The Management of Primary Aldosteronism: case detection, diagnosis, and treatment: an Endocrine Society clinical practice guideline. *J Clin Endocrinol Metab*. 2016;101(5):1889–916.
- Williams TA, Reincke M. Management of endocrine disease: diagnosis and management of primary aldosteronism: the Endocrine Society guideline 2016 revisited. *Eur J Endocrinol*. 2018;179(1):R19–29.
- Monticone S, Satoh F, Dietz AS, Goupil R, Lang K, Pizzolo F, Gordon RD, Morimoto R, Reincke M, Stowasser M, et al. Clinical management and outcomes of adrenal hemorrhage following adrenal vein sampling in primary Aldosteronism. *Hypertension*. 2016;67(1):146–52.
- Deinum J, Groenewoud H, van der Wilt GJ, Lenzini L, Rossi GP. Adrenal venous sampling: cosyntropin stimulation or not? *Eur J Endocrinol*. 2019;181(3):D15–26.
- Chayovan T, Limumpornpetch P, Hongsakul K. Success rate of adrenal venous sampling and predictors for success: a retrospective study. *Pol J Radiol*. 2019;84:e136–41.
- Jakobsson H, Farmaki K, Sakinis A, Ehn O, Johannsson G, Ragnarsson O. Adrenal venous sampling: the learning curve of a single interventionalist with 282 consecutive procedures. *Diagn Interv Radiol*. 2018;24(2):89–93.
- Morita S, Yamazaki H, Sonoyama Y, Nishina Y, Ichihara A, Sakai S. Successful adrenal venous sampling by non-experts with reference to CT images. *Cardiovasc Intervent Radiol*. 2016;39(7):1001–6.
- Rossi GP, Auchus RJ, Brown M, Lenders JW, Naruse M, Plouin PF, Satoh F, Young WF Jr. An expert consensus statement on use of adrenal vein sampling for the subtyping of primary aldosteronism. *Hypertension*. 2014;63(1):151–60.
- Park JS, Ahn HK, Na J, Lee HH, Yoon YE, Yoon MG, Han WK. Cumulative sum analysis of learning curve for video-assisted mini-laparotomy partial nephrectomy in renal cell carcinoma. *Medicine (Baltimore)*. 2019;98(17):e15367.

15. Rossi GP, Rossitto G, Amar L, Azizi M, Riestler A, Reincke M, Degenhart C, Widimsky J Jr, Naruse M, Deinum J, et al. Clinical outcomes of 1625 patients with primary Aldosteronism subtyped with adrenal vein sampling. *Hypertension*. 2019;74(4):800–8.
16. Vonend O, Ockenfels N, Gao X, Allolio B, Lang K, Mai K, Quack I, Saleh A, Degenhart C, Seufert J, et al. Adrenal venous sampling: evaluation of the German Conn's registry. *Hypertension*. 2011;57(5):990–5.
17. Siracuse JJ, Gill HL, Epelboym I, Clarke NC, Kabutey NK, Kim IK, Lee JA, Morrissey NJ. The vascular surgeon's experience with adrenal venous sampling for the diagnosis of primary hyperaldosteronism. *Ann Vasc Surg*. 2014;28(5):1266–70.
18. Xu J, Sheng C, Li M, Shen W, Tang X, Zhu L, Gao P, Wang J. A feasibility study on percutaneous forearm vein access for adrenal venous sampling. *J Hum Hypertens*. 2017;31(1):76–8.
19. Morita S, Yamamoto T, Kamoshida K, Yamazaki H, Suzuki K, Yatabe M, Ichihara A, Sakai S. Safety and feasibility of unilateral double femoral venous access including double sheath insertion via a single-hole method for adrenal venous sampling. *Jpn J Radiol*. 2020;38(8):800–6.
20. Miotto D, De Toni R, Pitter G, Seccia TM, Motta R, Vincenzi M, Feltrin G, Rossi GP. Impact of accessory hepatic veins on adrenal vein sampling for identification of surgically curable primary aldosteronism. *Hypertension*. 2009;54(4):885–9.
21. Matsuura T, Takase K, Ota H, Yamada T, Sato A, Satoh F, Takahashi S. Radiologic anatomy of the right adrenal vein: preliminary experience with MDCT. *AJR Am J Roentgenol*. 2008;191(2):402–8.
22. Omura K, Ota H, Takahashi Y, Matsuura T, Seiji K, Arai Y, Morimoto R, Satoh F, Takase K. Anatomical variations of the right adrenal vein: concordance between multidetector computed tomography and catheter venography. *Hypertension*. 2017;69(3):428–34.

Publisher's Note

Springer Nature remains neutral with regard to jurisdictional claims in published maps and institutional affiliations.

Ready to submit your research? Choose BMC and benefit from:

- fast, convenient online submission
- thorough peer review by experienced researchers in your field
- rapid publication on acceptance
- support for research data, including large and complex data types
- gold Open Access which fosters wider collaboration and increased citations
- maximum visibility for your research: over 100M website views per year

At BMC, research is always in progress.

Learn more biomedcentral.com/submissions

